

GAIT DISORDERS IN PATIENTS WITH INSTRUMENTED NEUROMUSCULAR SCOLIOSIS

DISTÚRBIOS DA MARCHA EM PACIENTES COM ESCOLIOSE NEUROMUSCULAR INSTRUMENTADA

DISTURBIOS DE LA MARCHA EN PACIENTES CON ESCOLIOSIS NEUROMUSCULAR INSTRUMENTADA

CARLOS DUNCAN,¹ SEBASTIAN MAENZA,¹ CECILIA SCHMID,¹ EDUARDO SEGAL,¹ JUAN COUTO¹

1. Department of Neuro Orthopaedics, FLENI, Buenos Aires, Argentina. FLENI (Fundación para la Lucha contra las Enfermedades Neurológicas de la Infancia). Montañeses 2325, Buenos Aires, Argentina.

ABSTRACT

Introduction: The effect of spinal fusion on gait in patients with neuromuscular scoliosis continues to be a controversial issue, especially in patients where the spinal fusion extends to the pelvis. **Objective:** To evaluate the effect of spinal instrumentation in these patients. **Methods:** We evaluated 34 patients in a retrospective study. The mean age at surgery was 14 ± 3 years and only ambulatory patients who presented neuromuscular scoliosis and non-progressing neurogenic pathology were included. The patients were surgically treated by posterior spinal fusion with or without extension to the pelvis. Preoperative (PRE) and postoperative (POP) Rx were measured. Ambulatory potential was clinically examined in all the patients, and 10 patients were assessed by full-gait analysis. **Results:** The minimum POP follow-up was 2 years (2006-2016). Nine patients were instrumented to the pelvis when the obliquity was greater than 15° ; the remaining patients were treated using the same fusion-level criteria as those applied for idiopathic scoliosis. All patients maintained their gait, with improvements in coronal and sagittal balance, transfers and sitting skills, physical appearance, and in some cases, gait speed. **Conclusions:** Spinal instrumentation in ambulatory patients with neuromuscular scoliosis, including procedures with extension to the pelvis, provides adequate correction and preserves ambulatory function. **Level of evidence III; Retrospective case control study.**

Keywords: Cerebral palsy; Scoliosis; Brain diseases.

RESUMO

Introdução: O impacto da fusão de coluna vertebral sobre a marcha de pacientes com escoliose neuromuscular continua sendo uma questão controversa, especialmente, em pacientes nos quais a fusão espinhal se estende até a pelve. **Objetivo:** Avaliar o efeito da instrumentação espinhal nesses pacientes. **Métodos:** Avaliamos 34 pacientes em estudo retrospectivo, com média de idade de 14 ± 3 anos à cirurgia; somente pacientes deambulatórios com escoliose neuromuscular e patologia neurogênica não progressiva foram incluídos. Os pacientes foram tratados cirurgicamente com fusão posterior da coluna com ou sem extensão até a pelve. Foram feitas radiografias pré-operatórias (PRE) e pós-operatórias (POP). O potencial deambulatório foi clinicamente examinado em todos os pacientes e 10 pacientes foram avaliados com análise completa em laboratório de marcha. **Resultados:** O acompanhamento mínimo do POP foi de 2 anos (2006-2016). Em nove pacientes foi realizada a instrumentação até a pelve quando a obliquidade era maior que 15° ; os demais pacientes foram tratados pelos mesmos critérios de nível de fusão aplicados à escoliose idiopática. Todos os pacientes mantiveram a marcha, com melhoras do balanço coronal e sagital, e transferências e capacidade para sentar, aparência física e, em alguns casos, na velocidade da marcha. **Conclusões:** A instrumentação da coluna vertebral em pacientes deambulatórios com escoliose neuromuscular, incluindo procedimentos com extensão até a pelve, proporciona correção adequada e preserva a função deambulatória. **Nível de evidência III; Estudo retrospectivo de caso-controle.**

Descritores: Paralisia cerebral; Escoliose; Encefalopatias.

RESUMEN

Introducción: El impacto de la fusión de columna vertebral sobre la marcha de pacientes con escoliosis neuromuscular continúa siendo una cuestión controversa, especialmente, en pacientes en los que la fusión espinal se extiende hasta la pelvis. **Objetivo:** Evaluar el efecto de la instrumentación espinal en esos pacientes. **Métodos:** Evaluamos 34 pacientes en estudio retrospectivo, con promedio de edad de 14 ± 3 años en el momento de la cirugía; fueron incluidos solamente pacientes ambulatorios con escoliosis neuromuscular y patología neurogénica no progresiva. Los pacientes fueron tratados quirúrgicamente con fusión posterior de la columna con o sin extensión hasta la pelvis. Fueron hechas radiografías preoperatorias (PRE) y postoperatorias (POP). El potencial ambulatorio fue clínicamente examinado en todos los pacientes y 10 pacientes fueron evaluados con análisis completo en laboratorio de marcha. **Resultados:** El acompañamiento mínimo del POP fue de 2 años (2006-2016). En nueve pacientes fue realizada la instrumentación hasta la pelvis cuando la oblicuidad era mayor que 15° ; los demás pacientes fueron tratados por los mismos criterios de nivel de fusión aplicados a la escoliosis idiopática. Todos los pacientes mantuvieron la marcha, con mejoras del balance coronal y sagital, y transferencias y capacidad para sentarse, apariencia física y, en algunos casos, en la velocidad de la marcha. **Conclusiones:** La instrumentación de la columna vertebral en pacientes ambulatorios con escoliosis neuromuscular, incluyendo procedimientos con extensión hasta la pelvis, proporciona corrección adecuada y preserva la función ambulatoria. **Nivel de evidencia III; Estudio retrospectivo de caso-controle.**

Descriptores: Parálisis cerebral; Escoliosis; Encefalopatías.

Study conducted at: FLENI - Fundación para la Lucha contra las Enfermedades Neurológicas de la Infancia, Buenos Aires, Argentina.

Correspondence: FLENI - Fundación para la Lucha contra las Enfermedades Neurológicas de la Infancia. Montañeses 2325, Buenos Aires, Argentina. carlos_duncan@hotmail.com



<http://dx.doi.org/10.1590/S1808-185120191804222791>

INTRODUCTION

Spinal deformity is a common disease in patients with Non-Progressive Chronic Encephalopathy (NPCE). Its incidence is proportional to the neurological involvement, affecting around 5% of diparetic patients and 64% to 74% of quadriparetic patients. These types of scoliosis are of usually early onset, with longer, less flexible and progressive curves that do not respond to conservative orthotic treatment. Patients may develop progressive decompensation of the trunk and pelvis, affecting standing position and gait and also compromising sitting when it is associated with pelvic obliquity.¹⁻⁴

Spinal fusion depends on multiple issues; it is recommended when there is a progressive curve of 50° or more in a patient ideally over 10 years of age. Extension to the pelvis is usually indicated when the obliquity is greater than 15°.^{3,4}

The effect of spinal fusion on gait in patients with neuromuscular scoliosis continues to be a controversial issue, especially when the procedure involves extension to the pelvis.¹ The purpose of this study is to evaluate the effect of spinal instrumentation in these patients.

METHODS

In this retrospective study (Level of evidence III), 34 ambulatory patients were evaluated; all the patients presented neuromuscular scoliosis, and were treated surgically by the same team between 2006 and 2016.

The mean age at surgery was 14±3 years (10 to 20 years); 25 patients were female and 9 male. All patients were ambulatory, with a “non-progressive” neurological diagnosis: 29 with Non-Progressive Chronic Encephalopathy (NPCE), 2 (sisters) with DiGeorge Syndrome, 2 with a history of Chiari type 1 malformation and Syringomyelia initially treated by neurosurgery, and 1 with spastic paraplegia as a consequence of a neuroblastoma resection at 4 months of age.

The curve patterns were divided into two groups using the classification of Lonstein and Akbarnia⁵ (Figure 1). Group I (Figures 1 A and B) (Figure 2) are thoracic curves or double thoracic/lumbar curves affecting the pelvis, for which the fusion criteria are similar to those for idiopathic scoliosis. These curves are more common in ambulatory patients with less severe neurologic involvement. Group II (Figures 1 C and D) (Figure 3) are long “C” shaped lumbar or thoracolumbar curves, associated with pelvic obliquity, and are frequent in non-ambulatory patients, and with fusion extending to the pelvis.

Using Surgimap Spine Software (Copyright 2013-2018), preoperative (PRE) and postoperative (POP) radiographs were evaluated.

The gait was clinically recorded in all the patients; additionally 10 of the patients were assessed pre- and post surgery by full-gait analysis. The data were recorded using BTS Bioengineering motion analysis software in the Gait lab, with a DX7000 capture system, 10 4M pixel infrared cameras, 6 P6000 force platforms, wireless surface electromyography, EMG with 10 wireless channels, and Pwalk BTS baropodometer.

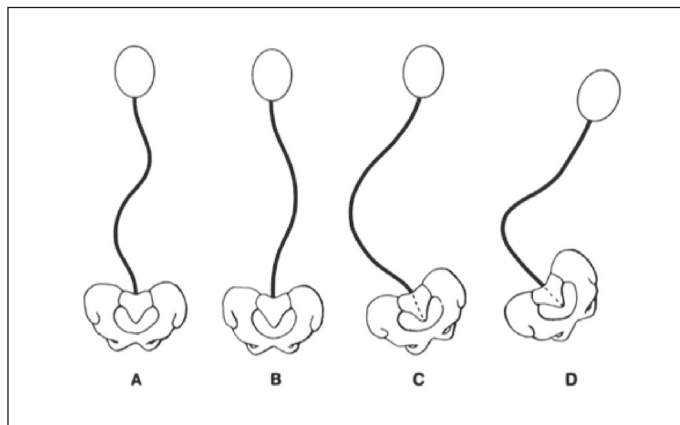


Figure 1. Curve patterns in Neurological Scoliosis according to Lonstein and Akbarnia.

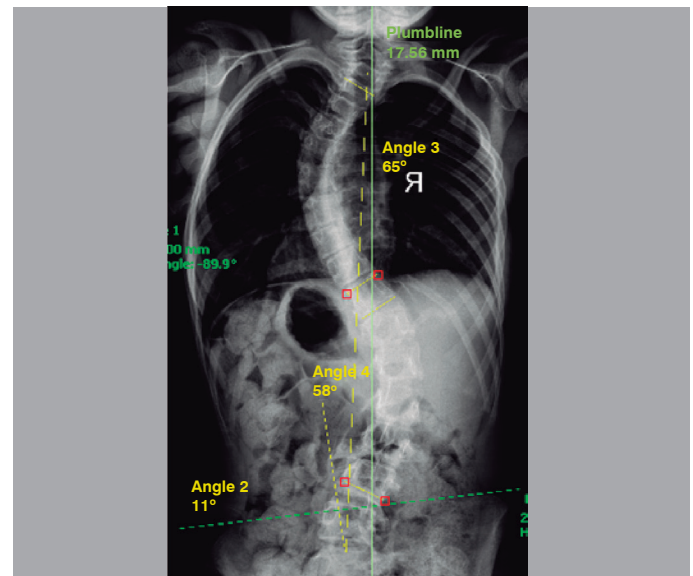


Figure 2. Group I Curve.

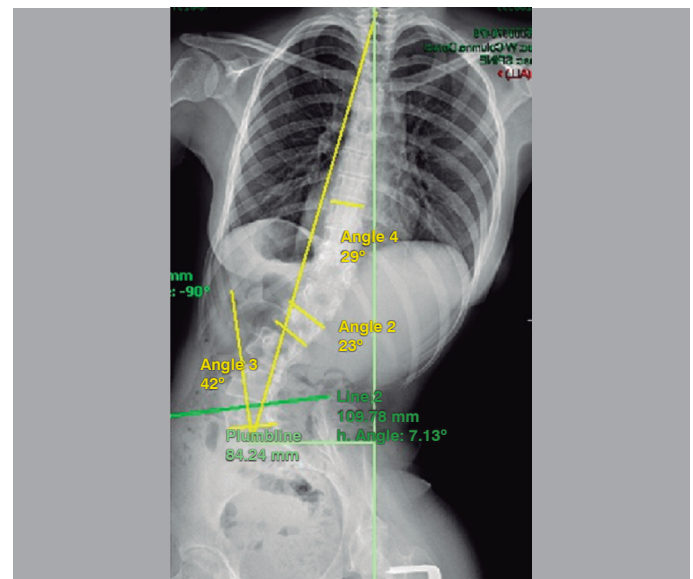


Figure 3. Group II Curve.

Intra- and postoperative complications were recorded.

The inclusion criteria were: ambulatory patients who presented neuromuscular scoliosis with a “non-progressive” diagnosis, surgically treated by posterior spinal fusion with or without extension to the pelvis, with a minimum postoperative follow-up of 24 months.

The exclusion criteria were non-ambulatory patients (i.e. wheelchair-dependent), with an underlying diagnosis of a progressive disease (e.g. Duchenne Muscular Dystrophy), those with myelomeningocele, and those with incomplete clinical history, follow-up or images.

The study participants signed the Free and Informed Consent Form. The work was not presented to the Ethics Committee of the Institution.

RESULTS

The minimum POP follow-up was 2 years (2006-2016).

Of the 34 patients, 25 (74%) were in Group I (Figure 4) (18 with thoracic curves and 7 with double thoracic/lumbar curves) and had spinal fusion that did not extend to the pelvis, and 9 (26%) were in Group II (Figure 5) with instrumentation extending to the pelvis.

The mean preoperative (PRE) and postoperative (POP) Scoliosis

(Cobb angles) were 67° and 21° respectively; the mean pelvic obliquity (reference curves Group II) values were 21° PRE and 3° POP. This represents a Cobb angle correction of 68.7% and Pelvic Obliquity of 85%.

There were complications in 4 cases (11.8%): 1 early infection (2.9%) and 3 reoperations (8.8%) (1 distal “adding on” progression, 1 shoulder level difference, and 1 due to insufficient pelvic de-rotation in the axial plane).

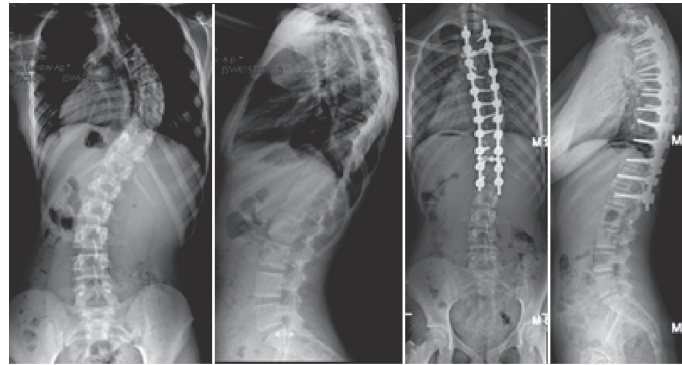


Figure 4. Example of curve treatment Group I. 12 year-old female patient with scoliosis secondary to Chiari malformation and syringomyelia.

All the patients maintained their gait, with improvements in coronal and sagittal spinopelvic balance, transfer skills, sitting, physical appearance, and in some cases, gait speed. In 10 patients, a pre- and postoperative gait analysis was performed (Figure 6).

DISCUSSION

The purpose of surgical treatment in idiopathic scoliosis is to obtain spinal correction and stabilization by fusing as few levels as possible. In neuromuscular scoliosis, these principles vary, with

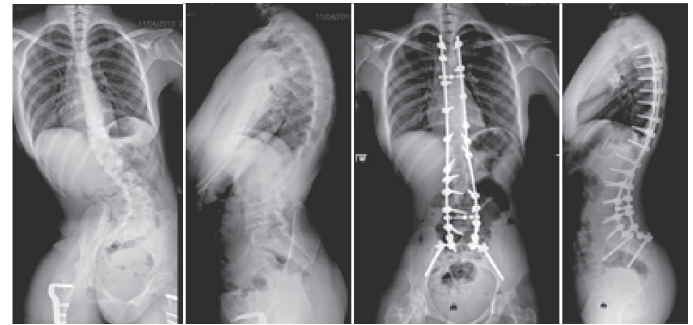


Figure 5. Example of curve treatment Group II. 16 year-old female patient with neurological scoliosis secondary to non-progressive chronic encephalopathy.

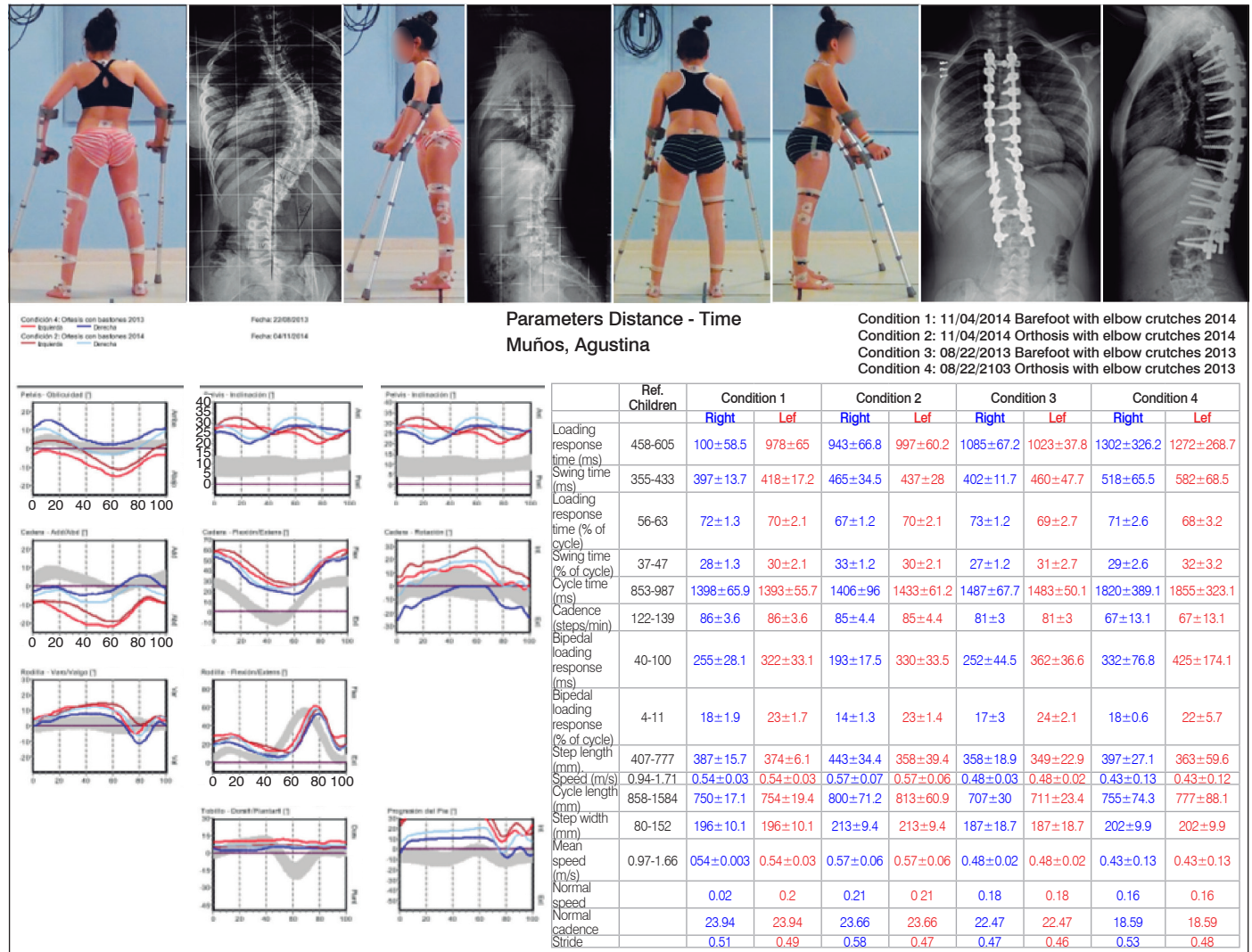


Figure 6. Summary of the Gait Lab in a 13 year-old female patient with a diagnosis of Non-Progressive Chronic Encephalopathy GMFCS III, comparing the pre- and post-scoliosis surgery results. The result of the study reports: similar gait pattern maintained, speed increased, lumbar hyperlordosis decreased, and better trunk alignment.

severe and progressive curves requiring longer fusions, extending to the pelvis in many cases, especially in non-ambulatory patients with pelvic obliquity.

There is a myth that fusions involving the pelvis compromise gait in ambulatory patients with neuromuscular scoliosis, and this issue remains controversial even today. This concept is probably associated with an instrumentation technique that was formerly used to treat these curves, which included Harrington rods that hindered sagittal balance, generating flat back and further complications. But these procedures were not rigid enough and required the use of casts, corsets and bed rest, all of which further compromised the patient's ability to stand and walk.⁶⁻¹²

There are few current bibliographic references related to this topic. Tsirikos et al.¹ published a comparable study in 2003, reporting a similar conclusion to ours. However, in their paper, all patients were fused to the pelvis, even in cases without pelvic obliquity, in order to obtain better correction and prevent a distal (adding on) progression. In our study, only patients with curves belonging to Group II of Lonstein and Akbarnia, and with pelvic obliquity greater than 15°, were fused to the pelvis. Patients belonging to Group I were treated similarly to idiopathic scoliosis; only one patient presented distal progression of the lumbar curve, probably due to an error in the choice of the distal fusion limit, with the initial instrumentation extending from T3-L2 to L4.

Clinical evaluation and the possibility of using a gait lab study, comparing the pre- and postoperative results in patients who also

underwent single event multilevel surgery (SEMLS) to the lower limbs, provides excellent information on their walking ability and allows adequate documentation of the results.

CONCLUSIONS

Our experience is based on the global neuro-orthopedic approach of the patient. Based on the evaluation of the results, we consider that those ambulatory patients with a "non-progressive" diagnosis who have developed neuromuscular scoliosis classified as Group I of Lonstein and Akbarnia, and with pelvic obliquity less than 15°, may be treated surgically with similar fusion limit criteria to those of idiopathic scoliosis. However, for patients in Group II, the instrumentation should include the pelvis. Following these criteria, in both cases, gait was not affected. Furthermore, based on kinematic, kinetic and neurophysiological records, the patient's functionality was optimized.

We consider that spinal fusion in ambulatory patients with neuromuscular scoliosis, with a "non-progressive" diagnosis; whether extending to the pelvis or not, provides correction, alignment, and balance of the coronal and sagittal planes, facilitating daily activities, preserving, and even optimizing the patients functional ability to walk.

All authors declare no potential conflict of interest related to this article.

CONTRIBUTION OF THE AUTHORS: Each author made significant individual contributions to this manuscript. CD (0000-0001-5689-0653)*, ES (0000-0002-1935-5536)*, and JC (0000-0003-0797-7781)* were the main contributors in writing the manuscript, performed the surgery and revised the manuscript and contributed to the intellectual concept of the study. SM (0000-0002-4867-0500)* and CS (0000-0002-9380-3130)* monitored the patients, collected clinical data, and carried out bibliographic research. *ORCID (Open Researcher and Contributor ID).

REFERENCES

1. Tsirikos AI, Chang WN, Shah SA, Dabney KW, Miller F. Preserving ambulatory potential in pediatric patients with cerebral palsy who undergo spinal fusion using unit rod instrumentation. *Spine (Phila Pa 1976)*. 2003;28(5):480-3.
2. Banta JV, Drummond DS, Ferguson RL. The treatment of neuromuscular scoliosis. *Instruct Course Lect*. 1999;48:551-61.
3. Lonstein JE. Spine deformities due to cerebral palsy. In: Weinstein SL, ed. *The Pediatric Spine: Principles and Practice*. Philadelphia: Lippincott Williams & Wilkins; 2001. p. 797-807.
4. McCarthy RE. Management of neuromuscular scoliosis. *Orthop Clin North Am*. 1999;30(3):435-49.
5. Lonstein JE, Akbarnia BA. Operative treatment of spinal deformities in patients with cerebral palsy or mental retardation. *J Bone Joint Surg*. 1983;65(1):43-55.
6. Dias RC, Miller F, Dabney K, Lipton GE. Revision spine surgery in children with cerebral palsy. *J Spinal Disord*. 1997;10(2):132-44.
7. Tokala DP, Lam KS, Freeman BJ, Webb JK. Is there a role for selective anterior instrumentation in neuromuscular scoliosis? *Eur Spine J*. 2007;16(1):91-6.
8. Basobas L, Mardjetko S, Hammerberg K, Lubicky J. Selective anterior fusion and instrumentation for the treatment of neuromuscular scoliosis. *Spine (Phila Pa 1976)*. 2003;28(20):S245-8.
9. Canavese F, Rousset M, Le Gledic B, Samba A, Dimeglio A. Surgical advances in the treatment of neuromuscular scoliosis. *World J Orthop*. 2014;5(2):124-33.
10. Maitra S, Roberto RF, McDonald CM, Gupta MC. Treatment of spine deformity in neuromuscular diseases. *Phys Med Rehabil Clin N Am*. 2012;23(4):869-83.
11. Sussman MD, Little D, Alley RM, McCoig JA. Posterior instrumentation and fusion of the thoracolumbar spine for treatment of neuromuscular scoliosis. *J Pediatr Orthop*. 1996;16(3):304-13.
12. Whitaker C, Burton DC, Asher M. Treatment of selected neuromuscular patients with posterior instrumentation and arthrodesis ending with lumbar pedicle screw anchorage. *Spine (Phila Pa 1976)*. 2000;25(18):2312-8.