

A look back into a typical patient with memory complains

Patricio Alexis Chrem Méndez¹ & Silvia Vázquez¹

¹ Neurology department,
Fleni (Buenos Aires,
Argentina)

Correspondence:

**Patricio Alexis Chrem
Mendez**

Neurology department,
Fleni (Buenos Aires,
Argentina)
E mail:
pchremmendez@fleni.org.ar

Aim: The purpose of these images is to extol the biological perspective from the clinical setting perspective of a typical AD case. This participant was profoundly studied and also followed-up for five years in the study ADNI- Argentina.

Clinical setting: The participant was 72 years old woman with an amnesic Mild Cognitive Impairment (MCI). She was enrolled in 2013, following the ADNI2 criteria as Late MCI. Her APOE status was 3/4, and scored 27/30 in the MMSE and 0.5 in CDR at baseline.

Biological Findings in CSF at Baseline: Aβ42 447 pg/ml; T-tau 599 pg/ml; P-tau 103 pg/ml; NfL 1124 pg/ml.

MRI at baseline: MTA 3/2, Fazekas 0, Koedam 1, Hippocampus volumes: L 2691, R 2318.

Conclusion: The molecular imaging revealed, beyond the clinician's eye, all the phenomena that had preceded the first clinical symptom. According to the new ATN scheme, the participant was positive in every aspect, and most probably, the whole process could have lasted around 15 years before its enrollment. After 60 months of follow-up the participant's MMSE was 15 and de CDR was 1. Sometimes an image can say a thousand words about the time that had elapsed when the physician first met the patient.

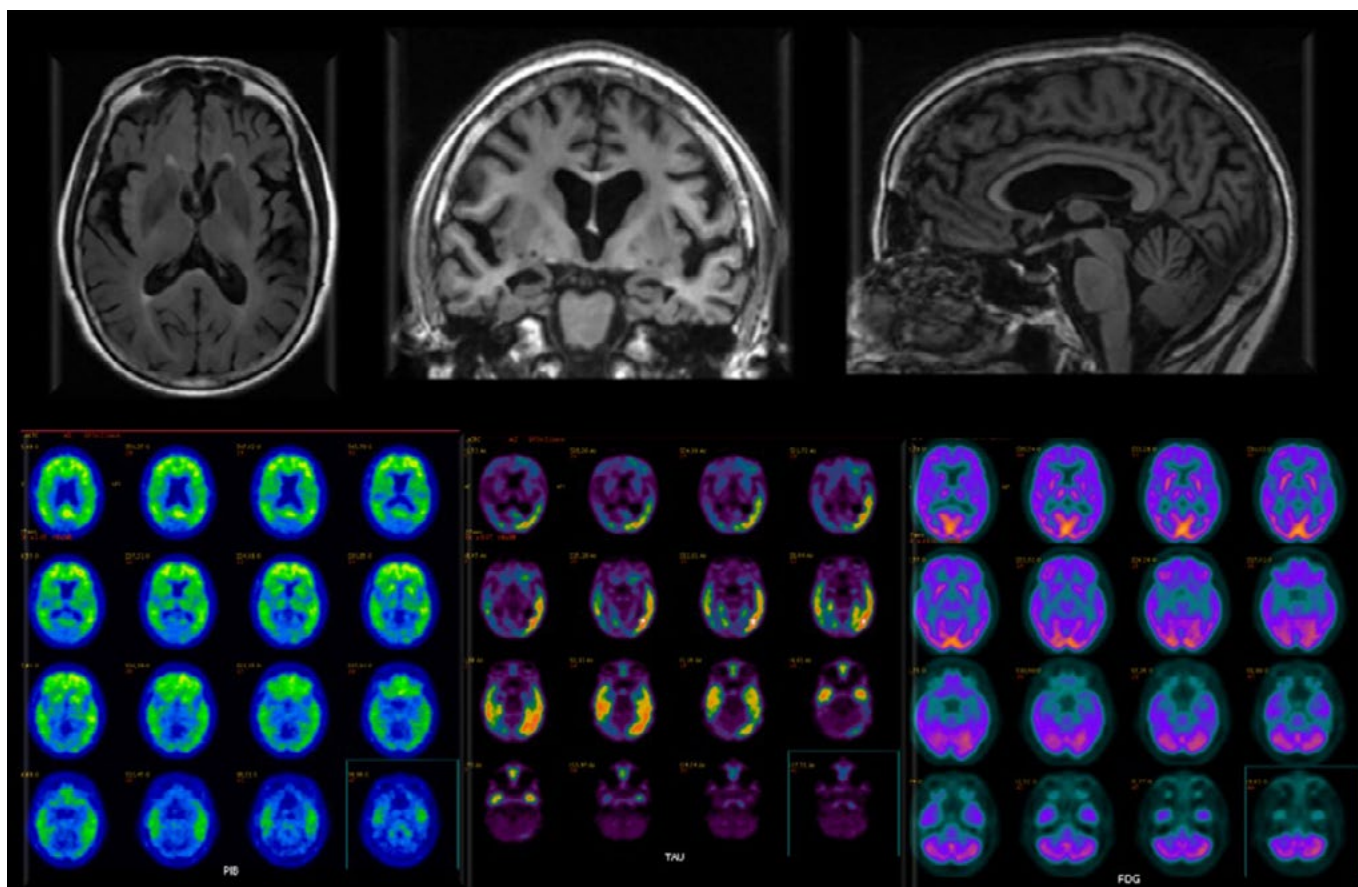


Figura 1. PET-PiB: A+, Tau-PET: T+, PET-FDG: N+
Source: Authors.

BIBLIOGRAPHY

- Aisen, P. S., Petersen, R. C., Donohue, M. & Weiner, M. W. (2015). Alzheimer's Disease Neuroimaging Initiative. Alzheimer's Disease Neuroimaging Initiative 2 Clinical Core: Progress and plans. *Alzheimers Dement*, 11(7), 734–739. <https://doi.org/10.1016/j.jalz.2015.05.005>
- Clifford, J., Bennett, D., Blennow, K., Carrillo, M., Dunn, B., Budd, S., Holtzman, D., Jagust, W., Jessen, F., Karlawish, J., Liu, E., Molinuevo, J., Montine, T., Phelps, C., Rankin, K., Rowe, C., Scheltens, P., Siemers, E., Snyder, H. & Sperling, R. (2018). NIA-AA Research Framework: Toward a biological definition of Alzheimer's disease. *Alzheimer's & Dementia*, 14(4), 535–562. <https://doi.org/10.1016/j.jalz.2018.02.018>

- Méndez, P., Calandri, I., Nahas, F., Russo, M., Demey, I., Martín, M., Clarens, M., Harris, P., Tapajoz, F., Campos, J., Surace, E., Martinetto, H., Ventrice, F., Cohen, G., Vázquez, S., Romero, C., Guinjoan, S., Allegri, R. & Sevlever, G. (2018). Argentina-Alzheimer's disease neuroimaging initiative (Arg-ADNI): neuropsychological evolution profile after one-year follow up. *Archivos de Neuropsiquiatria*, 76(4), 231–240. <https://doi.org/10.1590/0004-282x20180025>
- Russo, M., Gustafson, D., Vázquez, S., Surace, E., Guinjoan, S., Allegri, R. F. & Sevlever, G. (2014). Argentina-Alzheimer's Disease Neuroimaging Initiative. Creation of the Argentina-Alzheimer's Disease Neuroimaging Initiative. *Alzheimer's & Dementia*, 10(1S), 84–87. <https://doi.org/10.1016/j.jalz.2013.09.015>

Patrico A. Chrem Méndez: Neurologist.

Siliva Vásquez: Medical Director Center for Molecular Imaging CIM (Buenos Aires, Argentina).